Simplifying Neurology for critical illness claims

Jeremy Hobart

Consultant Neurologist and Senior Lecturer
Peninsula College of Medicine and Dentistry
Cheltenham 04 December 2008

Overview

1. Multiple sclerosis
2. Parkinson's disease and its looky-likeys
3. Brain tumours

Multiple Sclerosis

Basics
Advances in diagnosis and treatment

Multiple Sclerosis – what is it ?

- Complex, unpredictable, neurological condition
- Pathology is inflammation (swelling), demyelination (loss of cell covering) and neuronal degeneration (brain cell loss)
- Wide range of interacting symptoms
- Progressive deterioration in most patients
- Major cause of disability in young adults
- Mechanisms of damage poorly understood (still)

Inflammation

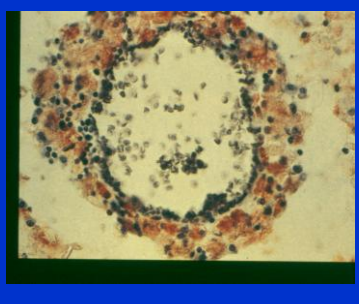

Demyelination

Neuronal degeneration

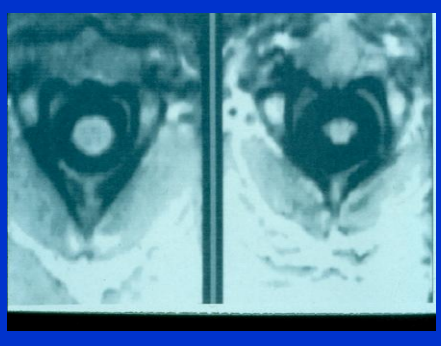

Symptoms in MS

- Cognitive dysfunction, Mood disturbance
- Reduced mobility: weakness, spasticity,ataxia
- Fatigue, heat intolerance
- Reduced dexterity
- Pain, sensory disturbance
- Bladder, bowel and sexual dysfunction
- Visual loss
- Speech, swallowing dysfunction

MS – age prevalence

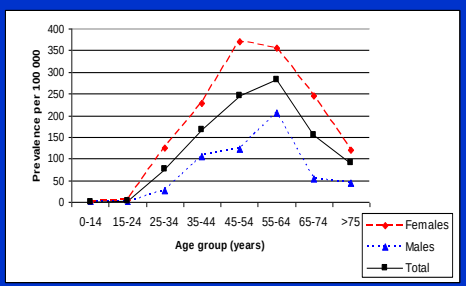

Comparison of percentage clinical concordance in studies of twins with muliple sclerosis

	n=	MZ twin	DZ twin	other sibling
Mumford	105	25	3	0
Ebers	70	26	2	2
Kinnunen	21	9	0	N/A
Williams	24	50	17	N/A
Heltburg	47	21	4	N/A

Clinical Courses in MS

Traditional diagnosis of MS requires 2 clinical episodes

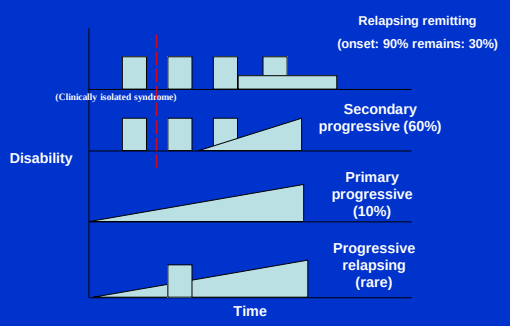

Diagnosing MS

Diagnosing MS in 2003

- MS remains a clinical diagnosis because there is no definitive test…

  (verified clinical evidence of neurological disturbance disseminated in time and place)

- ……..supported by laboratory information

  (investigation-based evidence of neurological disturbance disseminated in time and place)

- ….and other potential causes actively excluded

Diagnosing MS in 2008

- MS remains a clinical diagnosis because there is no definitive test…

  (verified clinical evidence of neurological disturbance disseminated in time and place)

- ……..supported by laboratory information according to increasingly explicit and simplifying guidelines

  (investigation-based evidence of neurological disturbance disseminated in time and place)

- ….and other potential causes actively excluded (consensus guidance)

Typical clinical scenario

- Fe(male) aged 40
- Episode of double vision 18 months ago
- Episode of blurred vision 3 months ago
- On examination…….

… and clinical video

Clinical picture

- 2 episodes of neurological disturbance each of which is appropriate for MS (..and 1 month rule)
- history suggests evidence of dissemination in time and space (ie different areas of "brain" at different times)
- History verified by clinical examination (important)
- Diagnosis of MS most likely (but need to exclude mimics)

Laboratory investigations in suspected MS

- MRI
- Visual evoked potentials (VEP / VER / EP's)
- Cerebrospinal fluid (CSF) examination [Lumbar puncture - LP]
- Copious blood tests

(none of these is diagnostic)

Evoked potentials

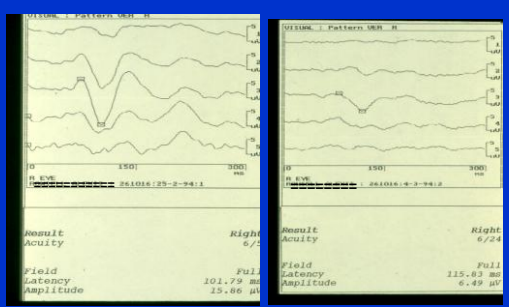

Lumbar puncture

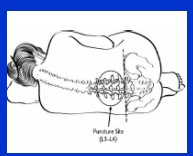

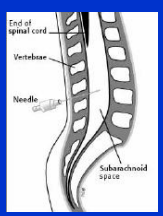

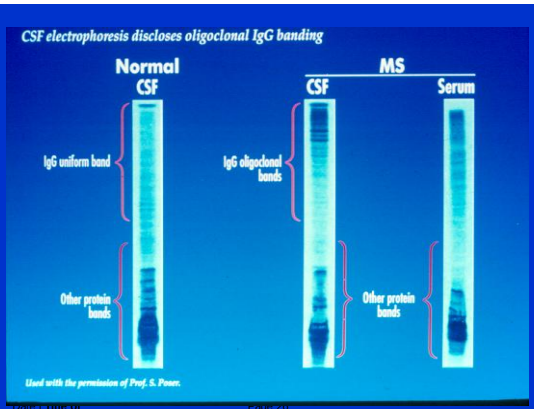

Magnetic Resonance Imaging (MRI)
Nuclear Magnetic Resonance (NMR)



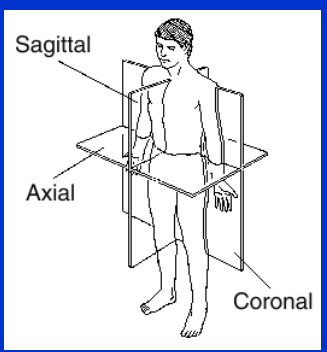
Sagittal
Axial
Coronal

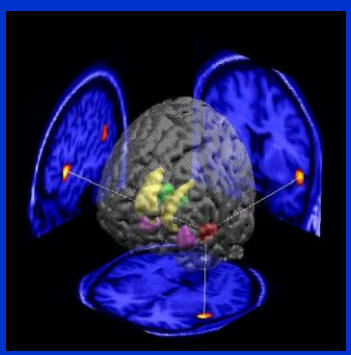

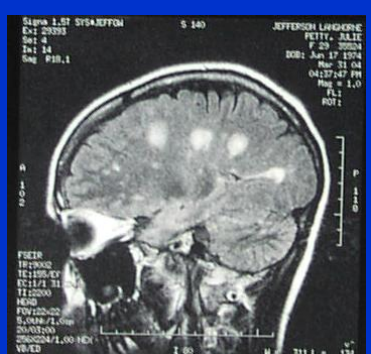

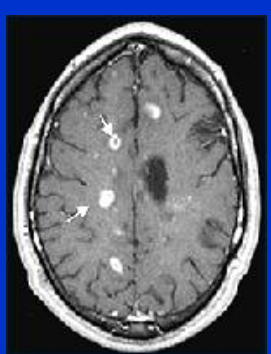

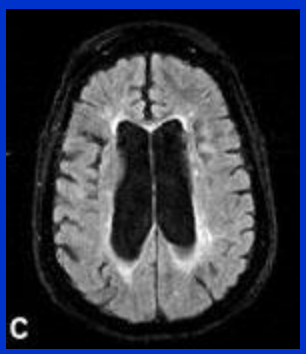

McDonald Criteria for MS

Attacks	Clinical lesions	Requirements for diagnosis MS
2 or more	2 or more	None
2 or more	1 lesion	**Dissemination in space demonstrated by MRI** (or CSF or await further attack)
1 attack	2 lesion	**Dissemination in time demonstrated by MRI** (or second clinical attack)
1 attack	1 lesion	**Dissem in space *and* time** demonstrated by MRI (or CSF and second attack)
0 attack Insidious neurological progression suggestive of MS		2 out of 3 of following: **Positive brain MRI** **Positive spinal cord MRI** **Positive CSF**

MRI in MS – it just gets simpler

	DIS*	DIT	Ref
McDonald 2001	≥3 of the following: 9 T2 lesions or 1 Gd-enhancing lesion; ≥3 periventricular lesions; ≥1 juxtacortical lesion; ≥1 posterior fossa lesion 1 spinal-cord lesion can replace 1 brain lesion	A Gd-enhancing lesion ≥3 months after CIS onset A new T2 lesion with reference to a previous scan ≥3 months after CIS onset	11
McDonald 2005	≥3 of the following: 9 T2 lesions or 1 Gd-enhancing lesion; ≥3 periventricular lesions; ≥1 juxtacortical lesion; ≥1 posterior fossa lesion or spinal-cord lesion A spinal-cord lesion can replace an infratentorial lesion Any number of spinal-cord lesions can be included in total lesion count	A Gd-enhancing lesion ≥3 months after CIS onset A new T2 lesion with reference to a baseline scan obtained ≥30 days after CIS onset	15
New criteria	≥1 lesion in each of ≥2 characteristic locations: periventricular, juxtacortical, posterior fossa, spinal cord All lesions in symptomatic region excluded in brainstem and spinal-cord syndromes	A new T2 lesion on follow-up MRI irrespective of timing of baseline scan	16

CIS=clinically isolated syndrome. Gd=gadolinium. *On baseline or follow-up MRI. The McDonald 2001 and 2005 DIS criteria also include the presence of two or more T2 lesions plus cerebrospinal fluid oligoclonal bands. Because cerebrospinal fluid was not examined systematically in the Magnims cohort, only the MRI criteria for DIS were used in this study.

Table 1: Three MRI criteria for dissemination in space (DIS) and dissemination in time (DIT) for multiple sclerosis

Treatments for MS

Treating MS 2003

Treatments for MS

- Symptomatic
- Disease modifying

Clinical Courses in MS

Traditional diagnosis of MS requires 2 clinical episodes

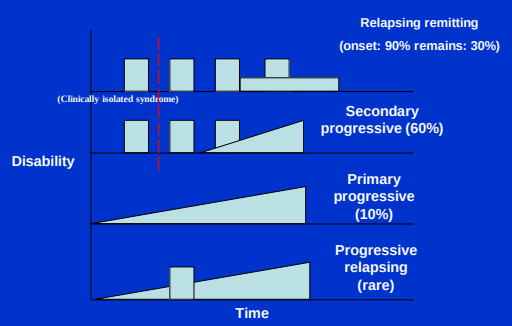

Treating MS 2008

Treatments for MS

- Symptomatic
- Disease modifying
  - Less aggressive
    Less effective
    Less side effects
  - More aggressive
    More effective
    More side effects

New aggressive treatments for MS

Monoclonal antibodies in MS

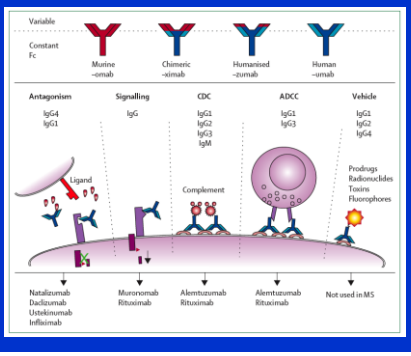

Monoclonal antibodies Hybridoma Technology

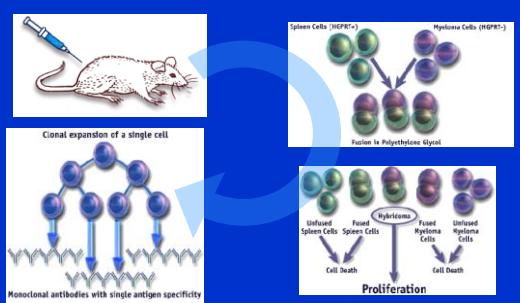

Campath-1H suppresses relapses in multiple sclerosis

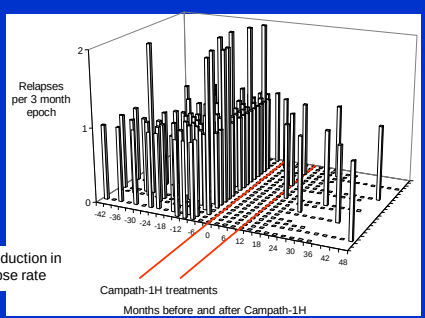

Alemtuzumab – 23 Oct 2008

Tysabri (natalizumab)

81% reduction in annualised relapse rate vs. placebo over 2 years ($p < 0.001$)

64% reduction in the risk of (sustained) disability progression as assessed over 2 years (p =0.008)

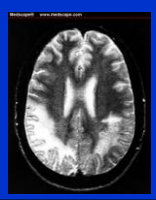

..but there is a price

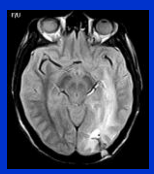

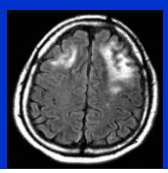

… a word on stem cells

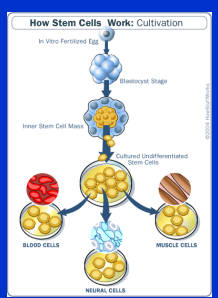

Parkinson's disease

Parkinson's disease

Parkinson's disease

Ideopathic parkinson's disease

Parkinsonism

Secondary parkinson's

Akinetic rigid syndromes

Parkinson's plus syndromes

Parkinson's disease
(ideopathic PD)
cardinal symtpoms

Tremor (2.4.1; 2.5.1)

Rigidity (2.4.2)

Akinesia (2.1.4; 2.6.1)

Postural changes

(hence aka Akinetic Rigid Syndrome..)

..and if that's not enough

The treatment can produce different problems that are worse……. (2.7.1)

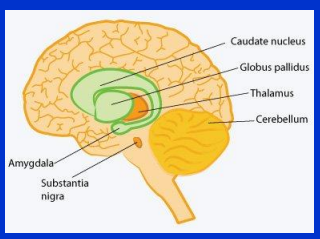
Caudate nucleus
Globus pallidus
Thalamus
Cerebellum
Amygdala
Substantia nigra

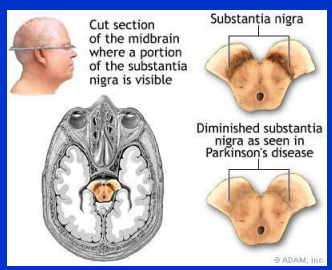
Cut section of the midbrain where a portion of the substantia nigra is visible
Substantia nigra
Diminished substantia nigra as seen in Parkinson's disease
© ADAM, Inc.

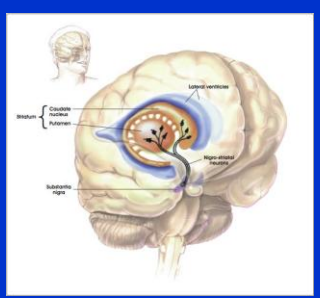
Lateral ventricles
Striatum
Caudate nucleus
Putamen
Nigro-striatal neurons
Substantia nigra

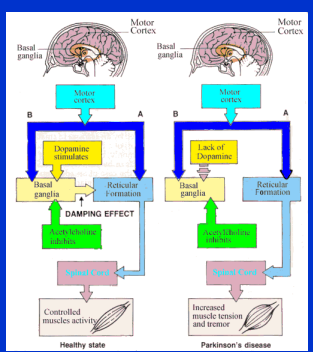
Motor Cortex
Basal ganglia
Motor cortex
B
A
Dopamine stimulates
Basal ganglia
Reticular Formation
DAMPING EFFECT
Spinal Cord
Controlled muscles activity
Healthy state
Motor Cortex
Basal ganglia
Motor cortex
B
A
Lack of Dopamine
Basal ganglia
Reticular Formation
Spinal Cord
Increased muscle tension and tremor
Parkinson's disease

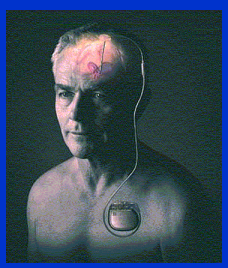

Akinetic rigid syndromes

Rigidity

Akinesia

+ other things

Tremor

Postural changes

Parkinsonism

- Primary (IPD) (n=1 diagnosis)
- Secondary to.. (n>45 other things)

Akinetic Rigid Syndromes

- IPD (n=1 diagnoses)
- PD+ (n>45 diagnoses)

2nd Parkinsonism
(ie parkinson's not due to IPD)

Progressive supranuclear palsy (3.3 3.4)

Multiple system atrophy

Small vessel cerebro-vascular disease

Huntington's disease

Alzheimer's disease

…and the > 40 other listed causes

2nd Parkinsonism

Vascular

Structural

Metabolic

Infection

Neuro-degenerative

Inherited metabolic

Trauma

1 and 2 Parkinsonism

Its not easy to tell them apart !

Lots of research based swanky tests can help

Formal diagnosis may be yrs after onset

Brain tumours

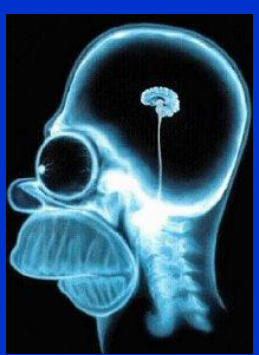

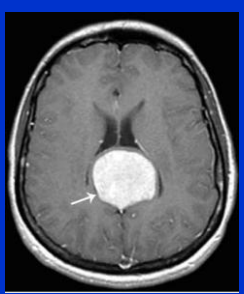

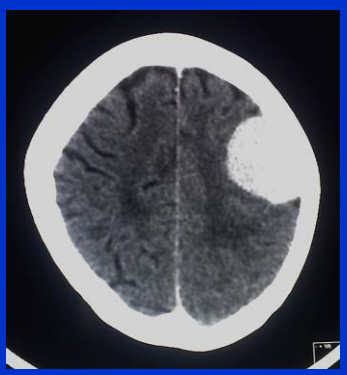

Benign or malignant?

- Its not so binary
- WHO classifications increasingly complex
- Cell type dependent
- 1 – 4 levels of aggression
- Histology required
- Increasingly molecular classifications
- Serial scanning valuable but fallible